

Accuracy of Robot-Assisted Pedicle Screw Placement for Adolescent Idiopathic Scoliosis in the Pediatric Population



Authors: Jeremy J. Macke M.D., Raymund Woo M.D., Laura Varich M.D.

Study Design

This is a retrospective review of pedicle screw placement in adolescent idiopathic scoliosis (AIS) patients under 18 years of age who underwent robot-assisted corrective surgery.

Objective

Our primary objective was to characterize the accuracy of pedicle screw placement by computed tomography (CT) after robot-assisted surgery in AIS patients.

Background

Screw malposition is the most frequent complication of pedicle screw placement and is more frequent in AIS. Given the potential for serious complications, the need for improved accuracy of screw placement has spurred multiple innovations including robot-assisted guidance devices.

Methods

Fifty patients were included in the study. All operative procedures were performed at a single institution by a single pediatric orthopedic surgeon. We evaluated the grade of screw breach, the direction of screw breach, and the positioning of the patient for preoperative scan.

Results

Of 662 screws evaluated, 7.2% demonstrated a breach of greater than 2mm. With preoperative prone position CT scanning, only 2.4% of screws were found to have this degree of breach. Medial malposition was found in 3% of screws, a rate which decreased to 0% with preoperative prone position scanning.

Conclusions

Based on our results, we conclude that the proper use of image-guided robot-assisted surgery can improve the accuracy and safety of thoracic pedicle screw placement in patients with adolescent idiopathic scoliosis. In our study, the robot-assisted screw misplacement rate was lower than similarly constructed studies evaluating conventional procedures. If patients are preoperatively scanned in the prone position, the misplacement rate is further decreased as this position simulates the patient's operative position.

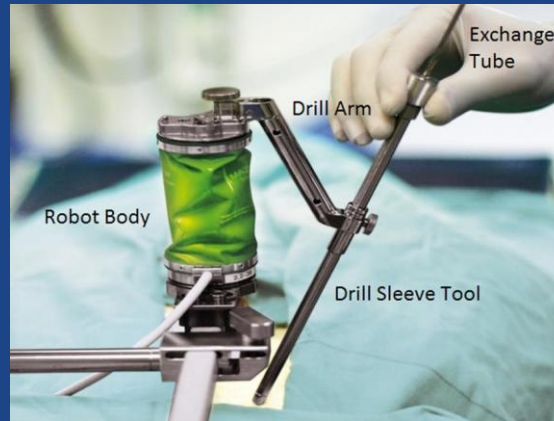


Figure 1
Title: Renaissance Robot

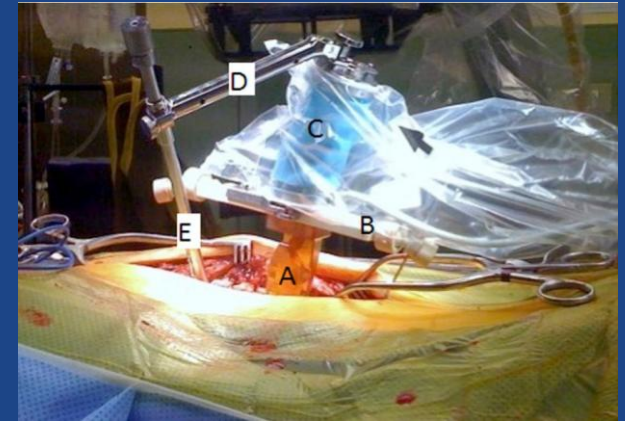
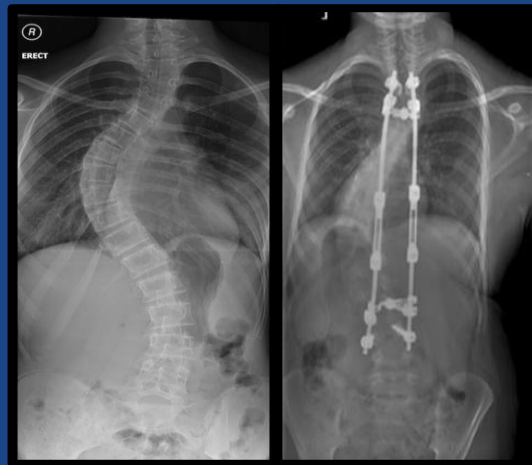

Figure 2
Title: Robot Mounted Intraoperatively

Legend:
A: Spinous process clamp. B: Bridge. C: Robot body. D: Drill arm. E: Drill sleeve tool



Key Points

1. This is the first study to evaluate the accuracy of pedicle screw placement using CT assessment in robot-assisted surgical correction of patients with AIS.
2. CT scanning demonstrated a screw misplacement rate lower than in similarly constructed studies evaluating conventional (non-robot-assisted) procedures.
3. Of 662 screws evaluated, 48 screws (7.2%) demonstrated a breach of greater than 2mm.
4. If preoperative scanning was performed in the prone position which simulates the patient's operative position, only 2.4% of screws were found to have a breach of greater than 2mm.
5. Medial malposition, found in 3% of screws, was decreased to 0% with preoperative prone CT positioning.