UNIVERSITY OF MIAMI
MILLER SCHOOL of MEDICINE

Supplemental Screening With Hand-Held Bilateral Breast Ultrasound Following A Negative Mammogram In Women With Dense Breast Tissue Who Are Not At High Risk For Breast Cancer

Jackson MEMORIAL HOSPITAL

AUTHORS

Geetika A. Klevos, MD; Mohammed Ezuddin, MD; Noam Alperin, PhD; Jose M. Net, MD; Monica M. Yepes, MD; Fernando Collado-Mesa, MD.

INSTITUTION

Department of Radiology
University of Miami Miller School of Medicine

INTRODUCTION

The sensitivity of screening mammography is affected by the presence of dense breast tissue (1-3). Some studies indicate that dense breast tissue affects breast cancer risk (4, 5). Hand-held breast ultrasound as a supplemental test to screening mammography in women with dense breast tissue has a reported incremental cancer detection rate of about 2–4/1,000 examined women (6-18). Several states in the US have enacted legislation requiring all women with dense breasts on mammography to be informed of their breast tissue density and that supplemental screening tests, such as breast ultrasound, should be discussed with them by their providers (19). This would entail supplemental screening of more than 40% of women over 40 years of age (20). Our purpose was to retrospectively assess the results of an initial round of supplemental screening with hand-held bilateral breast ultrasound performed following a negative bilateral screening mammogram in asymptomatic women with dense breast tissue and to at high of breast cancer (21).

METHODS

A retrospective, HIPAA-compliant, IRB-approved study was performed at a single academic tertiary breast center. Informed consent was waived. A systematic review of the center's database was performed. All asymptomatic women not at high risk for breast cancer who, on screening bilateral mammogram performed from July 1, 2010 through June 30, 2012 were found to have heterogeneously dense or extremely dense breast tissue and who received a mammographic final assessment BI-RADS category 1 or BI-RADS category 2 and whether they were recommended and obtained a subsequent adjunct screening breast ultrasound. Hand-held screening breast ultrasound was performed initially by a technologist and then by a radiologist. Results of the breast ultrasound and any procedures recommended based on the ultrasound were retrieved. Chi-square and t-test were used and statistical significance considered at $p<0.05$.

RESULTS

A total of 394 women underwent screening ultrasound. BI-RADS category 3 was assigned to 50 women (12.9 %) and 26 women (6.6 %) received BIRADS category 4. The differences found in some of the risk factors between groups (based on whether supplemental screening ultrasound was offered or not and based on whether ultrasound was performed or not) result in a mixed risk profile, with lower risk of breast cancer in those women in which the paragraph offering supplemental screening was added to their report (younger and less time of exposure to endogenous estrogens), and higher risk in those who came for the supplemental exam (more prevalent use of hormones). A total of 26 biopsies/aspirations were performed. The most common finding for which biopsy was recommend was solid mass (88.5%) with average size of 0.9 cm (0.5-1.7 cm). No carcinoma was found. The most frequent pathology result was fibroadenoma (60.8%).

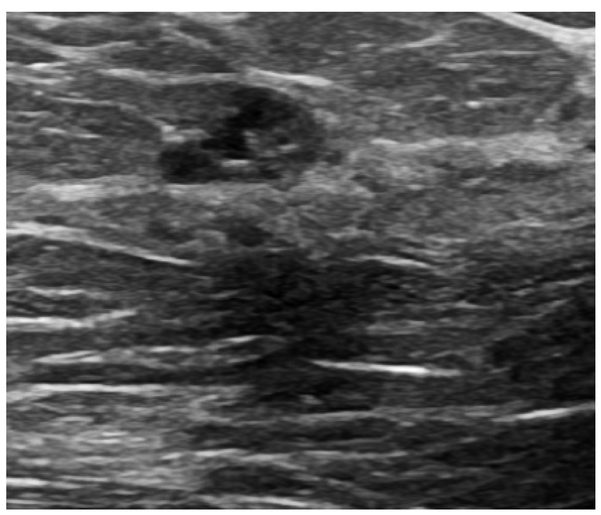

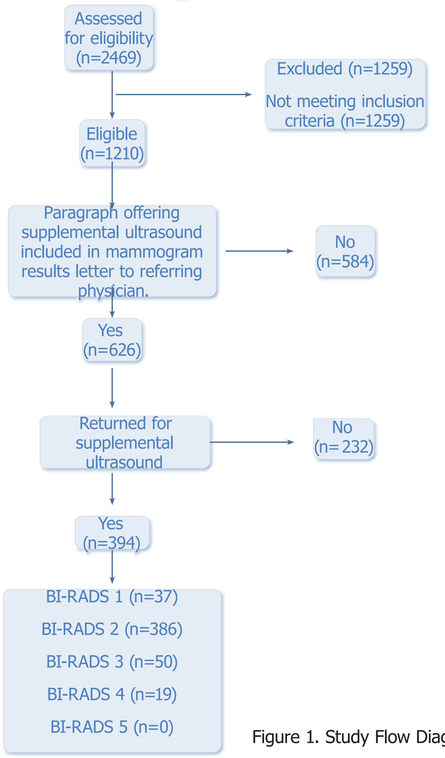

Figure 1. Study Flow Diagram.

Variable	Screening breast ultrasound offered (n=626)	Screening breast ultrasound not offered (n=584)	p	Screening breast ultrasound obtained n=394)	Screening breast ultrasound not obtained (n=232)	p
Age	48.1 ± 9.2	51.9 ± 9.5	<0.0001	47.3±9.2 years	49.4±9.4 years	0.006
Race			0.611			0.113
AA	116 (18.5%)	123 (21.0%)		57 (14.4%)	33 (13.7%)	
Hispanic	200 (31.9%)	188 (32.2%)		133 (33.7%)	78 (33.6%)	
White n-H	216 (34.5%)	184 (31.5%)		150 (38.0%)	87 (37.5%)	
Other	94 (15.0%)	89 (15.2%)		54 (13.7%)	34 (14.6%)	
Family history of breast cancer	108 (17.2 %)	84 (14.3 %)	0.172	76 (19.6%)	32 (13.6%)	0.079
Age at menarche	12.9 ± 1.6	12.7 ± 1.7	0.783	12.9 ± 1.7	12.8 ± 1.8	0.487
Hormone use	119 (19.0%)	77 (13.1%)	0.006	80 (20.6%)	39 (16.6%)	0.282
Parous	242 (38.6%)	198 (33.9%)	0.086	191 (48.4%)	102 (43.9%)	0.509
Age at first child	34.2±3.5	33.7±3.8	0.269	34.1±3.2	34.3±3.9	0.699
History of breast biopsy	163 (26.0%)	146 (25.0%)	0.679	67 (17.0%)	35 (15.1%)	0.593
History of high risk breast lesion	11(1.8%)	6 (1.1%)	0.281	10 (2.5%)	5 (2.1%)	0.768
Post-menopausal	338 (54.0%)	329 (56.3%)	0.413	206 (52.2%)	132 (56.8%)	0.264
Age at menopause	46.6±6.2	47.6±5.4	0.002	46.6±6.2	46.5±6.1	0.844

Table 1. Demographics and breast cancer risk factors.

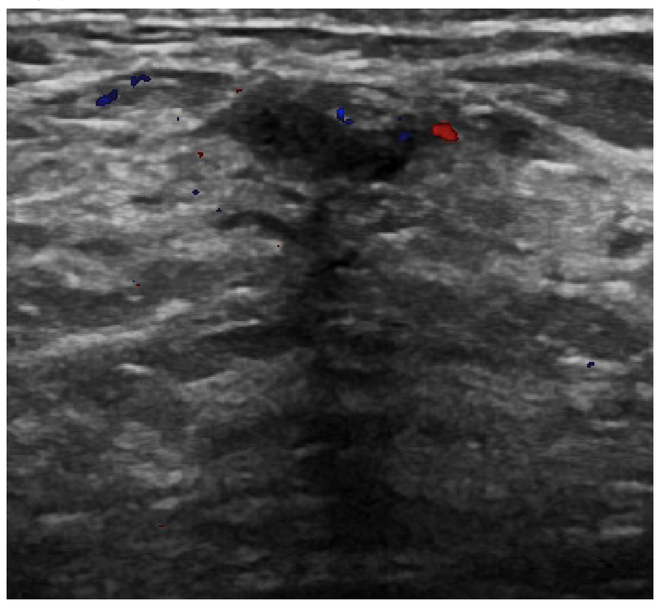

US BIRADS	Ultrasound finding	Size (cm)	Shape	Margins	Internal echogenicity	Orientation	Posterior acoustic features	Biopsy results
3 *	Mass	0.7	Oval	Circumscribed	Hypoechoic	Parallel	None	Fibroadenoma
3 *	Mass	1.4	Oval	Circumscribed	Hypoechoic	Parallel	None	Fibroadenoma
4A	Mass	0.9	Oval	Circumscribed	Hypoechoic	Parallel	None	Fibroadenoma
4A	Mass	0.9	Oval	Circumscribed	Hypoechoic	Parallel	None	Fibroadenoma
4A	Septated cyst							Fibrocystic changes
4A	Mass	0.9	Oval	Lobulated	Hypoechoic	Parallel	None	Fibroadenoma
4A	Mass	1.0	Oval	Circumscribed	Hypoechoic	Parallel	Shadowing	Fibroadenoma
4A	Mass	0.7	Oval	Circumscribed	Hypoechoic	Parallel	None	Fibroadenoma
4A	Complicated cyst							Fluid not suspicious
4A	Complicated cyst							Fluid not suspicious
4A	Mass	1.2	Lobulated	Lobulated	Hypoechoic	Parallel	None	Fibroadenoma
4A	Mass	1.0	Oval	Circumscribed	Hypoechoic	Parallel	None	Fibroadenoma
4A	Mass	1.0	Lobulated	Microcysts	Mixed	Parallel	None	Apocrine microcysts
4A	Mass	1.0	Oval	Circumscribed	Hypoechoic	Parallel	None	Fibroadenoma
4B	Mass	0.6	Irregular	Angular	Hypoechoic	Parallel	None	No evidence of carcinoma
4B	Mass	1.1	Irregular	Angular	Hypoechoic	Parallel	None	Fibroadenoma
4B	Mass	1.0	Irregular	Angular	Hypoechoic	Parallel	None	Fibrocystic changes
4B	Mass	1.0	Irregular	Indistinct	Hypoechoic	Parallel	None	Fibroadenoma
4C	Mass	1.7	Irregular	Angular	Hypoechoic	Parallel	Shadowing	Stromal fibrosis
4C	Architectural distortion	0.7	Irregular	Irregular	Hypoechoic	Not parallel	Shadowing	Stromal fibrosis
4C	Mass	0.5	Irregular	Irregular	Hypoechoic	Not parallel	Shadowing	Stromal fibrosis
Recommended/performed at 6 month follow-up								
4A	Mass	1.2	Oval	Circumscribed	Hypoechoic	Parallel	None	Fibroadenoma
4A	Mass	1.0	Oval	Circumscribed	Hypoechoic	Parallel	None	Stromal fibrosis
4A	Mass	1.6	Oval	Circumscribed	Hypoechoic	Parallel	None	Fibroadenoma
4B	Mass	0.8	Round	Microlobulated	Hypoechoic	Not parallel	Shadowing	Stromal fibrosis
Recommended/performed at 12 month follow-up								
4B	Mass	0.9	Oval	Microlobulated	Hypoechoic	Parallel	None	Adenosis

Table 2. False positive results by ultrasound BI-RADS category, descriptors and biopsy results.

DISCUSSION

Our study includes only asymptomatic women with dense breast tissue who are not at high risk for breast cancer, which represent the majority of women with dense breast tissue who undergo screening mammography for breast cancer. Some prior studies have only included women at high risk of breast cancer, while others have included symptomatic women and unilateral breast ultrasound obtained in women with known mammographic abnormalities in the contralateral breast or even in a different quadrant of the ipsilateral breast (6-18). Prior studies show differences in the qualification of the ultrasound exam performers, with some performed only by the radiologist only, some only by the technologist only, and some by both (6-18). Performing the supplemental hand-held screening breast ultrasound consecutively by two performers; first by a technologist and then by the interpreting radiologist, as in our study, likely serves to elucidate most mammographically occult findings, however it is time consuming and represents a burden on resources rendering this approach not feasible in clinical practice. An important methodological similarity between our study and some of the prior studies is using the biopsy results and the results of a one year follow-up as reference standard to access for false negative results, including the occurrence of interval cancers (10-13). Participants in our study were slightly younger (mean age of 47.3 years) as compared to those in other studies with a mean age of participants ranging from 51.2 to 55.2 years (10, 12, 16-18). Similarities to the results of previous studies include a similar proportion of BI-RADS categories 1, 2, and 3; a similar biopsy rate, and the fact that benign results in general and fibroadenoma and stromal fibrosis in particular accounted for most pathology findings (6, 9). Also similar to prior studies is the small size of the ultrasound findings for which further evaluation with biopsy was recommended (6-18). Our relatively small sample size is most likely responsible for the fact that no carcinoma was found. Of all prior studies only one study has a population size smaller than ours. However, unlike our study, that study included participants with a personal history of breast cancer which may have accounted for the additional breast carcinomas found with supplemental ultrasound. (13).

Ultrasound BI-RADS Assessment Category	At initial screening bilateral breast ultrasound	At 1st short-term follow-up at 6 months for BI-RADS 3	At 2nd short-term follow-up at 12 months for BI-RADS 3
	(n=394)	(n=50)	(n=36)
1	37 (9.5 %)	0	0
2	286 (72.6 %)	10 (17.6 %)	11 (55.5)
3	50 (12.9 %)	36 (70.5 %)	23 (30.5 %)
4	19 (4.8 %)	4 (9.8 %)	1 (2.7 %)
5	0	0	0
Loss to follow-up	N/a	1 of 50 (1.9 %)	1 of 36 (2.7 %)

[1] n/a Not applicable

Table 3. BI-RADS category at initial round of supplemental screening breast ultrasound and at recommended subsequent short-term follow-ups.

CONCLUSION

Our results support the reported occurrence of a relatively high number of false positives at supplemental screening with breast ultrasound following a negative screening mammogram in asymptomatic women with dense breast tissue not at high risk for breast cancer. This should be taken into consideration when planning to establish this type of supplemental screening for all women with dense breast tissue.

ACKNOWLEDGMENTS

The authors thank Jessica Schmidtman, Rachel Franklyn, Veronica Betancur and Claire Stauffer for their assistance in data collection.

REFERENCES

1. Breast Imaging Reporting and Data System. 4th ed. Reston: American College of Radiology; 2003.
2. Carney PA, Miglioretti DL, Yankaskas BC, Kerlikowske K, Rosenberg R, Rutter CM, et al. Individual and combined effects of age, breast density, and hormone replacement therapy use on the accuracy of screening mammography. Ann Intern Med. 2003;138:168-75. [PMID: 12558355]
3. Boyd NF, Guo H, Martin LJ, Sun L, Stone J, Fishell E, et al. Mammographic density and the risk and detection of breast cancer. N Engl J Med. 2007;356:227-36. [PMID: 17229950]
4. Tice JA, Cummings SR, Smith-Bindman R, Ichikawa L, Barlow WE, Kerlikowske K. Using clinical factors and mammographic breast density to estimate breast cancer risk: development and validation of a new predictive model. Ann Intern Med. 2008;148:337-47. [PMID:18316752]
5. Pisano ED, Gatsonis C, Hendrick E, Yaffe M, Baum JK, Acharyya S, et al; Digital Mammographic Imaging Screening Trial (DMIST) Investigators Group. Diagnostic performance of digital versus film mammography for breast-cancer screening. N Engl J Med. 2005;353:1773-83. [PMID: 16169887].
6. Kaplan SS. Clinical utility of bilateral whole-breast US in the evaluation of women with dense breast tissue. Radiology. 2001;221:641–9.
7. Kolb TM, Lichy J, Newhouse JH. Comparison of the performance of screening mammography, physical examination, and US and evaluation of factors that influence them: an analysis of 27,825 patient evaluations. Radiology. 2002;225:165–75.
8. Crystal P, Strano SD, Shcharynski S, Koretz MJ. Using sonography to screen women with mammographically dense breasts. AJR Am J Roentgenol. 2003; 181:177–82.
9. Berg WA, Blume JD, Cormack JB, et al. Combined screening with ultrasound and mammography vs mammography alone in women at elevated risk of breast cancer. JAMA. 2008;299:2151–63.
10. Berg WA, Zhang Z, Lehrer D, Jong RA, Pisano ED, Barr RG, et al. Detection of breast cancer with addition of annual screening ultrasound or a single screening MRI to mammography in women with elevated breast cancer risk. JAMA 2012;307(13):1394-404. PMID: 22474203
11. Corsetti V, Houssami N, Ghirardi M, Ferrari A, Speziani M, Bellarosa S, et al. Evidence of the effect of adjunct ultrasound screening in women with mammography-negative dense breasts: interval breast cancers at 1 year follow-up. Eur J Cancer. 2011;47(7):1021-6. PMID: 21211962
12. Hooley RJ, Greenberg KL, Stackhouse RM, Geisel JL, Butler RS, Philpotts LE. Screening US in patients with mammographically dense breasts: initial experience with Connecticut Public Act 09-41. Radiology. 2012;265(1):59-69. PMID: 22723501
13. Leong LC, Gogna A, Pant R, Ng FC, Sim LS. Supplementary breast ultrasound screening in Asian women with negative but dense mammograms-a pilot study. Ann Acad Med Singapore 2012;41(10):432-9. PMID: 23138139
14. Youk JH, Kim EK, Kim MJ, Kwak JY, Son EJ. Performance of hand-held whole-breast ultrasound based on BI-RADS in women with mammographically negative dense breast. Eur Radiol. 2011; 21(4):667-75. PMID: 20853108
15. Brancato B, Bonardi R, Catarzi S, Iacconi C, Risso G, Taschini R, et al. Negligible advantages and excess costs of routine addition of breast ultrasonography to mammography in dense breasts. Tumori. 2007;93(6):562-6. PMID: 18338490
16. Girardi V, Tonegutti M, Ciatto S, Bonetti F. Breast ultrasound in 22,131 asymptomatic women with negative mammography. Breast. 2013; 22(5):806-9. PMID: 23558244
17. Parris T, Wakefield D, Frimmer H. Real world performance of screening breast ultrasound following enactment of Connecticut Bill 458. Breast J 2013;19(1):64-70. PMID: 23240937
18. Weigert J, Steenbergen S. The Connecticut experiment: the role of ultrasound in the screening of women with dense breasts. Breast J. 2012;18(6):517-22. PMID: 23009208.
19. Are you Dense? Advocacy. D.E.N.S.E. ® State Efforts. 2014 [Accessed August 30, 2015]; Available from: http://www.areyoudenseadvocacy.org/dense/.
20. Sprague BL, Gangnon RE, Burt V, Trentham-Dietz A, Hampton JM, Wellman RD, et al. Prevalence of mammographically dense breasts in the United States. J Natl Cancer Inst. 2014; 106. [PMID: 25217577] doi:10.1093/jnci/dju255.
21. American College of Radiology. ACR Appropriateness Criteria®. 2012 [Accessed August 30, 2015]